

Effective Treatment of Perianal Tumors in Dogs with Electrochemotherapy

NATASA TOZON¹, VERONIKA KODRE², GREGOR SERSA³ and MAJA CEMAZAR³

¹University of Ljubljana, Veterinary Faculty, Small Animal Clinic, Cesta v Mestni log 47, SI-1000 Ljubljana;

²Janssen-Cilag, Division of Johnson-Johnson, Smartinska 140, 1000 Ljubljana;

³Institute of Oncology, Zaloska 2, SI-1000 Ljubljana, Slovenia

Abstract. *Background:* Electrochemotherapy is an antitumor therapy that utilizes locally-delivered, short intense direct current electric pulse to the tumor nodule plus chemotherapy. The aim of the present study was to evaluate the electrochemotherapy treatment of perianal tumors of different sizes in dogs. *Materials and Methods:* In 12 dogs, 26 tumor nodules of perianal tumors of different size, and clinically expected to be of different histological type, were treated with electrochemotherapy. Electrochemotherapy consisted of intratumoral injection of cisplatin (1mg/cm³) or bleomycin (3mg/cm³), followed by application of electric pulses (8 electric pulses; amplitude, 910 V, duration, 100 μ s, frequency, 1 Hz) to the tumor nodule. *Results:* Responses to treatment were assessed 4 weeks after the therapy; 82% of all tumors treated with electrochemotherapy responded with objective response (OR) (complete response (CR)=41%, partial response (PR)=41%), 16% responded with no change (NC) and 1 tumor (2%) went to progressive disease (PD). At the end of the observation period for each tumor, ranging from 1 to 34 months, 92% OR (CR=65%, PR=27%), 8% NC and no PD were obtained. No major local or general side-effects were noted. *Conclusion:* Electrochemotherapy with cisplatin or bleomycin is an effective treatment of perianal tumors in dogs. The advantages of this therapy are its simplicity, short duration of treatment sessions, low chemotherapeutic doses and insignificant side-effects, as well as the fact that the subject does not have to stay in hospital.

Perianal tumors (circumanal, hepatoid tumors) are very common in male and rare in female dogs. Perianal adenomas comprise more than 80% of the perianal tumors and are the

third most common tumor in male dogs. Older, intact (not castrated) males are at high risk for perianal adenomas, implying an androgen dependency, whereas perianal adenocarcinoma occurs in castrated or intact males, implying no hormonal dependency (1). The perianal adenocarcinomas look similar to adenomas but tend to grow faster, are firmer, more frequently ulcerated, usually adhere to the anal and rectal tissues and recur following treatment (1). Adenomas are more prevalent in the Cocker spaniel, beagle, bulldog and Samoyed (1). In a study performed on 41 dogs, perianal adenocarcinomas were more common in Siberian huskies and less common in German shepherd dogs, arctic circle breeds other than huskies and dogs weighing more than 35 kg (2).

Adenomas and hyperplasia can regress in up to 95% of cases following castration, however, suspected nodules should be biopsied for a definite histopathological diagnosis (2). In addition, adenomas and hyperplasia can regress following estrogen therapy. However, the potential risk of severe myelosuppression following estrogen therapy limits its use (2). Perianal adenocarcinomas do not regress following castration, and are not responsive to hormonal therapy with estrogens. Dogs with small perianal adenocarcinomas, without lymph node involvement and distant metastases, treated by wide surgical excision, have a survival of approximately 70% at 2 years (2). In the case of more progressive disease, the survival of dogs is between 7 (dogs with distant metastases) and 24 months (dogs with lymph node involvement only). In a limited number of cases, after surgical excision, lymphadenectomy, intraoperative radiation to the lymph node bed and external beam radiation to the lymph node may be useful in slowing progression of the disease (1). Since cost and availability of radiation makes this treatment a last alternative with most clinicians, there is a need for new treatment modalities to achieve better tumor control and lower morbidity due to the aggressiveness of the treatment (1).

Electrochemotherapy is an antitumor therapy that utilizes locally-delivered, short intense direct current electric pulse to the tumor nodule combined with chemotherapy (3).

Correspondence to: Prof. Maja Cemazar, Ph.D., Institute of Oncology Ljubljana, Zaloska 2, SI-1000 Ljubljana, Slovenia. Tel/Fax: + 386(0)1 5879 434, e-mail: mcemazar@onko-i.si

Key Words: Dogs, cancer, chemotherapy, cisplatin, bleomycin, electroporation.

Application of electric pulses causes a nonselective increase in plasma membrane permeability and therefore facilitates and increases uptake of the drugs that act on intracellular targets, which otherwise have impaired uptake into the cells (3-5). The increased drug uptake results in increased antitumor effectiveness. Electrochemotherapy using either bleomycin or cisplatin has been extensively tested in preclinical studies and has entered clinical phase I and II studies in human patients, where it proved to be a highly effective antitumor treatment (3-8). There are only a few studies that used electrochemotherapy with either cisplatin or bleomycin for the treatment of spontaneous tumors in companion animals (9-12). These studies showed that electrochemotherapy is an effective treatment for histologically different malignant tumors in dogs, cats and horses (9-12).

The aim of the present study was to evaluate the effectiveness of electrochemotherapy on perianal tumors in dogs. Tumor nodules of different sizes were treated with cisplatin or bleomycin delivered intratumorally and immediately thereafter exposed to electric pulses.

Materials and Methods

Subject selection. Between March 2000 and July 2003, 12 male dogs were treated with electrochemotherapy (Table I). National Ethics Committee approval and written informed consent from each owner were obtained before the beginning of treatment. The dogs had to possess measurable cutaneous or subcutaneous nodules, for which the owners had refused standard treatment, *i.e.* surgery or systemic chemotherapy. Eligibility criteria also included dogs with normal blood tests and biochemistry. Dogs with radiographic or ultrasonographically visible visceral metastases were not included.

Study design. The aim of the study was to evaluate the antitumor effectiveness of electrochemotherapy, *i.e.* intratumoral administration of cisplatin followed by delivery of electric pulses to the tumor nodule. The results of our previous study (9) showed no or very weak response of tumors treated with intratumoral injection of cisplatin alone in comparison with tumors treated with electrochemotherapy. Therefore, it would be unethical not to perform electrochemotherapy on all accessible tumor nodules, especially because the treatment was used with curative intent. The treatment was performed on perianal tumor nodules (adenoma or adenocarcinoma) of different sizes. Electrochemotherapy with bleomycin given intratumorally was performed when tumor nodules bigger than 1 cm³ regrew in 4 weeks after electrochemotherapy with cisplatin. In the case of tumor nodules smaller than 1 cm³, electrochemotherapy with bleomycin was performed when the tumors had ulcerative wounds and tended to bleed after electrochemotherapy with cisplatin, or remained at the same volume and with same ulcerative surface as before electrochemotherapy with cisplatin. A summary of the treatment parameters is given in Tables II and III.

Electrochemotherapy treatment. Before treatment, the dogs were sedated by *i.m.* injection of 100 µg/kg bw medetomidine hydrochloride (Dormitor, Pfizer GmbH Karlsruhe, Germany).

Table I. Summary of subject characteristics—dogs with perianal tumors.

Subject No.	Breed	Age/sex	No. of tumors	Observation time (months)
1	Middle Schnauzer	9/Male	2 (a,b)	32
2	Cocker spaniel	12/Male	1	24
3	Karst shepherd	10/Male	1	10
4	German shepherd	14/Male	3 (a,b,c)	1 (euthanasia)
5	German shepherd	11/Male	3 (a,b,c)	2 (euthanasia)
6	Cocker spaniel	13/Male	3 (a,b,c)	4
7	Cross-breed	11/Male	1	25
8	Cross-breed	14/Male	3 (a,b,c)	12
9	Poodle	13/Male	1	12
10	Cross-breed	10/Male	1	34
11	Fox terrier	14/Male	4 (a,b,c,d)	13
12	Middle Schnauzer	11/Male	3 (a,b,c)	11

Electrochemotherapy consisted of intratumoral administration of *cis*-diamminedichloroplatinum II (Platinol, Bristol-Myers, Munich, Germany; cisplatin) and exposure of the tumor nodules to electric pulses. Cisplatin was dissolved in distilled water at a concentration of 2 mg/ml. Cisplatin was given intratumorally at approximately 1 mg/cm³ tumor volume (Tables II, III). Bleomycin (Blenoxane, Bristol-Myers, Munich, Germany) as the second choice drug was dissolved in physiological saline at 3 mg/ml and was given intratumorally at approximately 3 mg/cm³ tumor volume (Tables II, III). The interval between cisplatin or bleomycin administration and the application of electric pulses was 1-2 min.

Square wave electric pulses of 100 µsec, 910 V amplitude (amplitude to electrode distance ratio 1300 V/cm), frequency 1 Hz were delivered through two parallel stainless steel electrodes (IGEA S.r.l., Carpi, Italy); thickness, 1 mm; width, 7 mm; length, 8 mm, with rounded tips and an inner distance between them of 7 mm) with an electropulsator Jouan GHT 1287 (Jouan, St Herblaine, France). Each run of electric pulses was delivered in 2 trains of 4 pulses, with 1-sec interval, in 2 perpendicular directions. Good contact between the electrodes and the skin was assured by depilation and application of a conductive gel to the treatment area.

Treatment evaluation. After treatment, the subjects were kept in the clinic for about 2 to 4 h. After that, they were examined weekly in order to evaluate the treatment effectiveness and possible local and systemic side-effects. At each visit, tumor nodules were measured with a Vernier caliper and photographed. The volume of tumor nodules was calculated by the formula $V = a \times b \times c \times \pi/6$, where *a*, *b* and *c* represent the diameters of the tumor nodule. Response to the treatment was scored after 4 weeks, according to WHO guidelines, as follows: complete response (CR), absence of any trace of tumor; partial response (PR), more than 50% reduction in tumor volume; no change (NC), reduction of tumor volume less than 50% and no enlargement more than 25%; and progressive disease (PD), tumor volume enlarged more than 25% (13). The number of objective responses (OR) was determined by combining the number of CR and PR. The observation time was calculated as the interval between the date of the first treatment and the date of the last examination.

Table II. Summary of treatment parameters and tumor response of perianal tumors with volume less than 1 cm³.

Subject no.	Nodule	ECT ^a session no.	CDDP ^b dose (mg/nodule)	No.of EP ^c /nodule	Nodule volume before ECT (cm ³)	Nodule volume after 4 weeks (cm ³)	Response after 4 weeks	Response at the end of observation	Nodule volume at the end of observation
1	a	1	0.6	2x(4+4)	0.60	0.30	PR		
		2	BLM ^d 1.2	1x(4+4)	0.30	0.20	NC		
		3	0.4	1x(4+4)	0.20	0.10	PR		
		4	BLM 0.9	1x(4+4)	0.12	0.05	PR	PR	0.05
	b	1	0.4	1x(4+4)	0.40	0.00	CR		
		2	BLM 0.3	1x(4+4)	0.10	0.03	PR		
		3	BLM 0.1	1x(4+4)	0.03	0.01	PR	PR	0.01
2	a	1	1.0	4x(4+4)	0.88	0.30	PR		
		2	0.6	1x(4+4)	0.30	0.00	CR	CR	-
3	a	1	1.0	3x(4+4)	0.82	0.08	PR		
		2	0.3	2x(4+4)	0.08	0.00	CR	CR	-
6	b	1	1.0	1x(4+4)	0.20	0.00	CR	CR	-
	c	1	2.0	1x(4+4)	0.50	0.00	CR	CR	-
7	a	1	0.6	4x(4+4)	0.65	0.10	PR		
		2	BLM 1.5	2x(4+4)	0.50	0.00	CR	CR	-
8	a	1	0.2	1x(4+4)	0.13	0.19	PD		
		2	0.2	1x(4+4)	0.19	0.00	CR	CR	-
	b	1	1.4	5x(4+4)	0.87	0.54	NC		
		2	0.6	4x(4+4)	0.54	0.00	CR	CR	-
	c	1	0.4	1x(4+4)	0.36	0.33	NC		
		2	0.4	3x(4+4)	0.33	0.00	CR	CR	-
9	a	1	1.0	2x(4+4)	0.89	0.00	CR	CR	-
11	b	1	0.3	1x(4+4)	0.30	0.00	CR	CR	-
		1	0.3	1x(4+4)	0.14	0.00	CR	CR	-
	d	1	0.4	1x(4+4)	0.30	0.00	CR	CR	-
12	a	1	0.5	2x(4+4)	0.60	0.00	CR	CR	-
		1	0.4	1x(4+4)	0.40	0.00	CR	CR	-
		1	0.2	1x(4+4)	0.20	0.00	CR	CR	-

^aECT=electrochemotherapy^bCDDP=cisplatin^cEP=electric pulses^dBLM = bleomycin

Results

Treatment response. In 12 dogs, 26 tumor nodules of different size were treated with electrochemotherapy, *i.e.* intratumoral administration of cisplatin followed by delivery of electric pulses to the tumor nodule. Electrochemotherapy with bleomycin given intratumorally was performed when tumor nodules bigger than 1 cm³ regrew in 4 weeks after electrochemotherapy with cisplatin. In the case of tumor nodules smaller than 1 cm³, electrochemotherapy with bleomycin was performed when the tumors had ulcerative wounds and tended to bleed after electrochemotherapy with cisplatin, or remained at the same volume and with same ulcerative surface as before electrochemotherapy with cisplatin. In order to compare the antitumor effectiveness of electrochemotherapy with regard to different tumor volumes, the tumors were divided into two groups: group with tumors smaller than 1 cm³ and tumors bigger than 1 cm³.

Electrochemotherapy of tumors smaller than 1 cm³ resulted in 86% OR 4 weeks after the treatment with 57% CR and 29% PR. At the end of the observation period for each tumor, ranging from 4 to 34 months (Table I), the percentage of CR increased to 88%, while in the rest of the tumors PR was obtained (12%) (Table II).

In most cases one electrochemotherapy session was needed to obtain CR, in 6 cases 2 electrochemotherapy sessions were performed and only 2 tumor nodules were treated 3 or 4 times. The interval between the treatments was either 4 or 8 weeks depending on tumor growth and also on the irregularity of the follow-up visits. Three tumor nodules (1a, 1b and 7a) became ulcerated and did not heal after electrochemotherapy with cisplatin. Therefore, in the next session bleomycin was used instead of cisplatin. Electrochemotherapy with bleomycin resulted in good tumor response in these nodules. One nodule (7a) responded completely, while the 2 others (1a and 1b) responded partially. This subject (#1) was castrated 28 months

Table III. Summary of treatment parameters and tumor response of perianal tumors with volume more than 1 cm³.

Subject no.	Nodule	ECT ^a session no.	CDDP ^b dose (mg/nodule)	No.of EP ^c /nodule	Nodule volume before ECT (cm ³)	Nodule volume after 4 weeks (cm ³)	Response after 4 weeks	Response at the end of observation	Nodule volume at the end of observation
4	a	1	10.0	18x(4+4)	10.00	5.93	PR		
		2	6.0	10x(4+4)	5.93	2.50	PR	PR	2.50
	b	1	10.0	18x(4+4)	10.00	7.67	NC		
		2	6.0	10x(4+4)	7.67	4.15	NC	NC	4.15
	c	1	6.0	5x(4+4)	5.00	4.15	NC		
		2	6.0	5x(4+4)	4.15	2.80	NC	NC	2.80
5	a	1	10.0	12x(4+4)	11.70	2.60	PR	PR	2.60
	b	1	6.0	12x(4+4)	12.80	5.09	PR	PR	5.09
	c	1	5.0	6x(4+4)	4.18	1.09	PR	PR	1.09
6	a	1	6.0	12x(4+4)	9.40	5.84	PR		
		2	6.0	14x(4+4)	5.84	2.90	PR		
		3	BLM ^d 6.0	8x(4+4)	6.11	3.60	PR	PR	3.60
10	a	1	1.0	4x(4+4)	1.10	0.07	PR		
		2	0.1	2x(4+4)	0.07	0.05	PR		
		3	BLM 0.1	2x(4+4)	0.05	0.00	CR	CR	0.00
11	a	1	1.0	2x(4+4)	1.04	0.00	CR	CR	0.00

^aECT=electrochemotherapy

^bCDDP=cisplatin

^cEP=electric pulses

^dBLM = bleomycin

after the last electrochemotherapy session, when the tumor volumes were still unchanged compared to the responses at 4 weeks after the last electrochemotherapy with bleomycin.

In the second group of tumors (tumor volume more than 1 cm³), electrochemotherapy was less effective. Four weeks after the treatment OR was obtained in 75% of tumors (CR=12.5%, PR=62.5%). The same percentage of OR was also obtained at the end of observation period with 22% CR and 56% PR (Table III). Due to the larger size of the tumors, up to 18 applications of electric pulses were needed to cover the whole tumor area in a single session. After the first session, tumor nodules in most cases responded partially. Therefore, additional electrochemotherapy sessions were performed on the remaining tumor nodule, resulting in a further reduction of tumor volume. In subjects 4 and 5, euthanasia was performed 1 and 2 months after the first electrochemotherapy session due to the owner's decision (subject 4) and development of perianal fistulas (subject 5). At the time of euthanasia, the nodules treated with electrochemotherapy were in PR or NC. In subject 6, the tumor was treated with 2 electrochemotherapy sessions with cisplatin and, after progression of the disease 8 weeks after the second electrochemotherapy session, electrochemotherapy with bleomycin was performed. Subsequently the tumor reduced by more than half in size (PR), which enabled surgical removal of the remaining nodule 4 months after the beginning of treatment. At the time of surgical removal of the tumor nodule, the dog was also castrated. This subject is

currently still free of disease (3.5+ years). The other two dogs 10 and 11, that had big tumor nodules, were successfully treated in 3 and in one electrochemotherapy session, respectively. In both subjects, long-term local control of tumor growth was achieved at 35 and 14 months, respectively.

Collectively, larger tumors had good response to the treatment with electrochemotherapy, but with less CR and more complications (larger necrosis, but without any systemic signs of inflammation) compared to smaller tumors (Figures 1, 2). Altogether, 4 weeks after the therapy, 82% of all tumors treated with electrochemotherapy were in OR (CR=41%, PR=41%) and only one of the tumors went to progressive disease (PD). At the end of observation period for each tumor (1 to 34 months), 92% of OR (CR=65%, PR=27%) was obtained, while the rest of the tumors were in NC (8%).

Treatment tolerance. No major local or general side-effects were noted. Muscle contractions were observed after application of each electric pulse. The contractions were instantaneous, disappearing immediately at the end of each electric pulse. The treatment with cisplatin or bleomycin given intratumorally did not result in any local or systemic toxicity. We noticed partial necrosis of the tumors after a week with the formation of a superficial scab, which fell off within 5 weeks (Figures 1, 2). After treatment, none of the subjects suffered from a local or systemic infection. The treatment had no effect on blood tests or biochemistry of the treated subjects.

Discussion

This study shows that electrochemotherapy with cisplatin or bleomycin is an effective treatment of perianal tumors in dogs. Treatment of perianal tumors with electrochemotherapy in our study resulted in 82% OR after 4 weeks (with 41% CR) and 92% OR at the end of observation period ranging from 1 to 34 months (with 65% CR). In addition, electrochemotherapy resulted in better tumor control in smaller tumors compared to tumors larger than 1 cm³.

Concerning the treatment procedure, electrochemotherapy is easy and quick to perform, and is inexpensive. The advantage of this treatment is that, by local potentiation of drug uptake by application of electric pulses, lower doses of the chemotherapeutic drugs are needed, which does not result in systemic side-effects. In chemotherapy, one of the major problems is how to bring a sufficient amount of chemotherapeutic drug into the tumor cells for effective cell killing, while minimizing the drug concentration in normal cells and, therefore, sparing normal tissues. In chemotherapy of small animals, myelosuppression and gastrointestinal toxicity are the most common side-effects. In dogs cisplatin can induce acute renal failure. However, saline diuresis prior to and following drug administration helps to minimize the risk of renal failure (14). Bleomycin can induce acute or delayed adverse effects, especially in combined systemic chemotherapy with other agents or combined with radiation therapy. Acute toxicities include fever, anorexia, vomiting and allergic reactions, including anaphylaxis. Delayed toxic effects include dermatological effects, stomatitis, pneumonia and pulmonary fibrosis (15). Many different approaches, aiming to make chemotherapy more safe and effective, are being developed and tested. In view of this, several attempts at selective tumor drug delivery have been made including: local application of the drugs, specific targeting of tumors by binding of the drugs to tumor-specific antibodies, incorporation of the drugs into liposomes or other vehicles, or by selectively increasing the permeability of the plasma membrane of tumor cells by employing either chemical (use of detergents) or physical methods (electroporation) (16-24). In our study, we combined two of these approaches: intratumoral injection of cisplatin or bleomycin and electroporation of tumor cells by the application of electric pulses to the tumor site.

There are also some other studies presenting good results in treating different malignancies in animals with electrochemotherapy. Mir *et al.* and colleagues used electrochemotherapy with bleomycin for treatment of cats with large soft-tissue sarcomas that suffered relapse after treatment with conventional therapies (10). Electric pulses were delivered after intravenous injection of 0.5 mg/kg bleomycin, using external surface electrodes, as well as needle-shaped electrodes that were designed to be inserted into the tumors for more

effective electric field distribution in the tissue. The cats' lifespan increased significantly compared with the control group of 11 untreated cats (10). Rols and colleagues showed 100% of OR of large sarcomas in horses treated by electrochemotherapy with cisplatin (11). All lesions disappeared after only 2 to 3 electrochemotherapy sessions and no regrowth was observed in the 18-month follow-up period. Our previous study on electrochemotherapy with cisplatin on different malignancies in dogs and cats also showed the effectiveness of this treatment (9). Treatment of mast cell tumors, fibrosarcoma, haemangioma, haemangiosarcoma, adenocarcinoma of glandule perianalis, mammary adenocarcinoma and neurofibroma resulted in 84% OR, while only one control tumor partially responded to cisplatin treatment alone, the rest of them being in progressive disease. In a recent study, Spugnini and Porrello showed that electrochemotherapy with intralesional bleomycin is an effective treatment for bulky tumors in dogs and cats. Compared to tumors that were treated with bleomycin only, electrochemotherapy resulted in significantly increased tumor response (80% OR obtained with electrochemotherapy compared to 30% obtained with bleomycin alone) (12).

Besides the advantages, there are also some disadvantages of electrochemotherapy. In human patients pain is a limiting factor (25). In animals pain can be avoided with sedation of the patient and by lifting the treated tumor nodule while applying electric pulses. There was also difference in sensation between the electrodes that had a smaller gap (4 mm) and induced less pain than those that had a bigger gap (7 mm), because electrodes with a smaller gap required lower electric field intensity for electroporation of the tissue. In addition, it was observed that obese human patients had less sensation, because adipose tissue prevented electric field distribution deeper into the underlying tissue, therefore less muscle contractions were observed (25). Another disadvantage of electrochemotherapy in veterinary medicine is the appearance of tumor necrosis, which is, in fact, a consequence of the successful treatment. The size of tumor necrosis depended on the size of the treated tumor. It is important to note that animals did not show any signs of pain due to the presence of necrosis. However, the animal owners had to be willing to maintain the wound toilet, but special wound dressing was not required. For owners unpleasant wound care was needed only for a short time, since approximately 1 week after the therapy the superficial scab developed, which fell off within 5 weeks in the case of CR of the tumor nodule. If the tumor nodule did not respond completely to the treatment, the electrochemotherapy session was repeated.

Veterinary medicine is still searching for the most appropriate and successful treatment of tumors in the perianal region. Surgery and castration seem to be insufficient, especially in subjects with malignant adenocarcinoma. Surgery can be combined with radiation therapy, but addition of

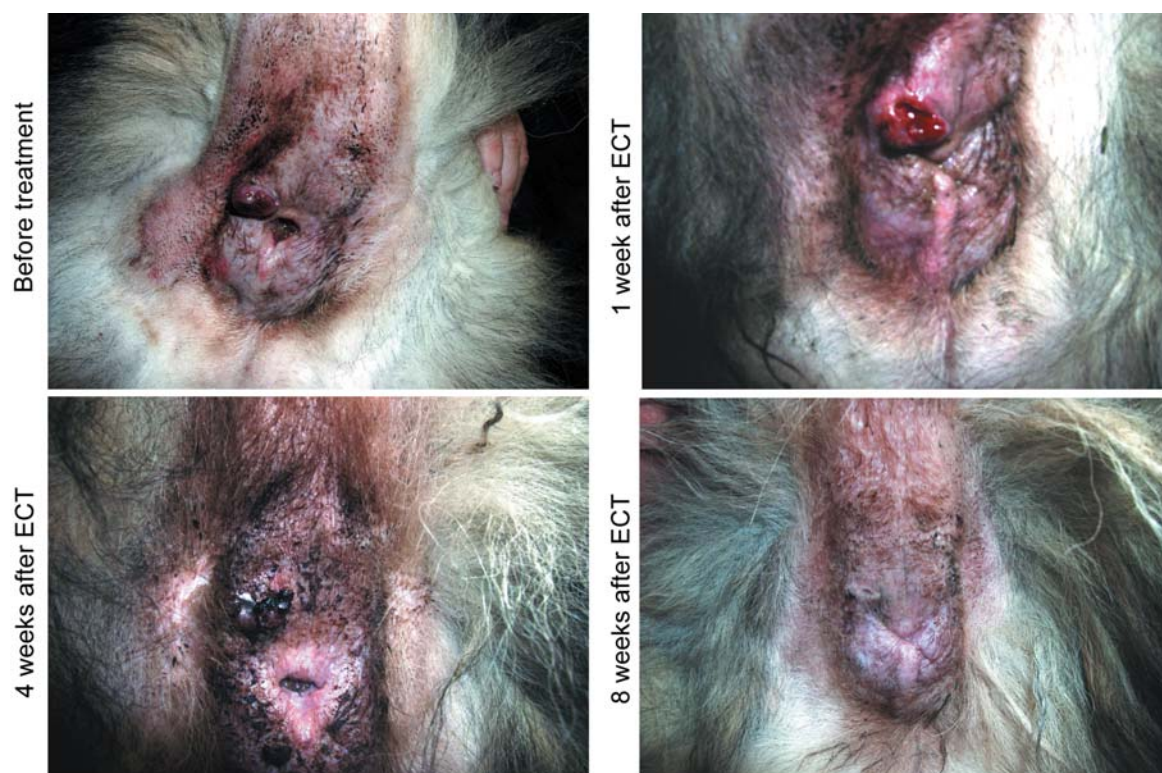

Figure 1. Antitumor effectiveness of electrochemotherapy (ECT). Subject 3 was treated 2 times by ECT with cisplatin at 4-week intervals. Good local control was obtained 8 weeks after the first ECT session.

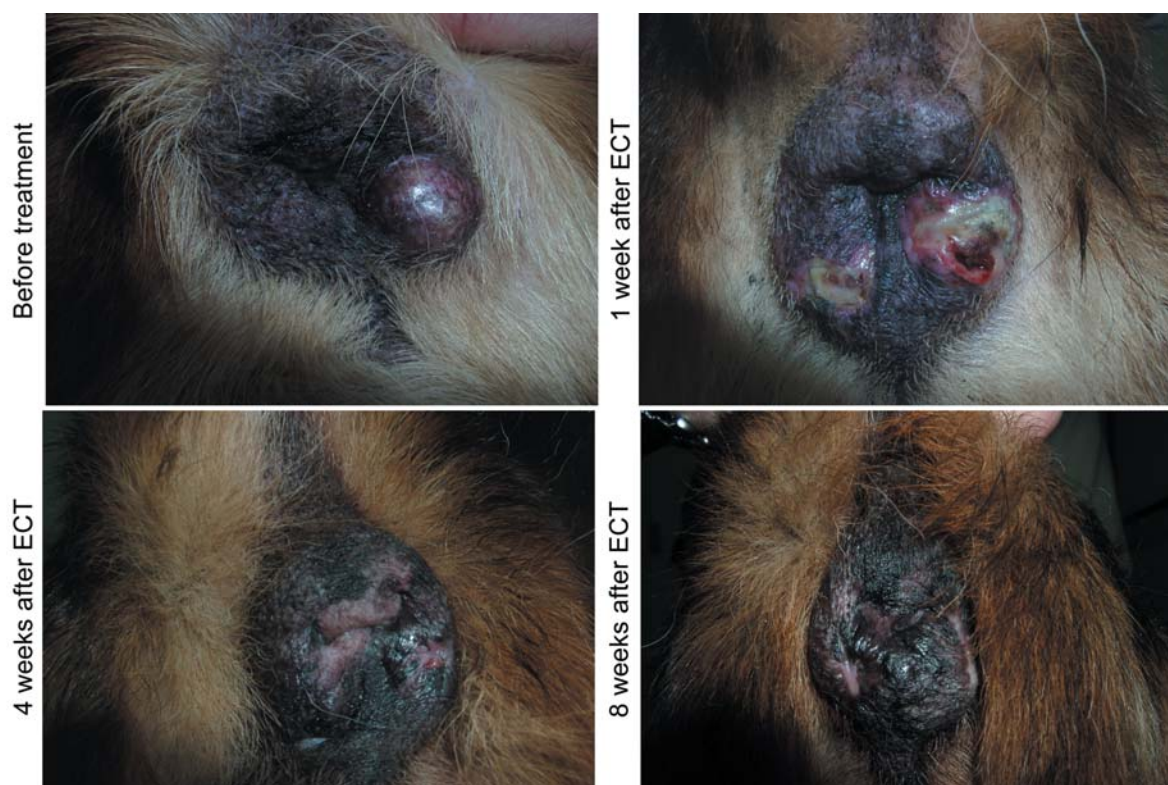


Figure 2. Antitumor effectiveness of electrochemotherapy (ECT). Subject 8 had 3 tumor nodules smaller than 1 cm^3 . Each tumor nodule was treated with two ECT sessions at 4-week intervals. Good local control was obtained 8 weeks after the first ECT session.

radiation therapy resulted in increased morbidity, can be performed only in specialized centers and is also very costly (26). In conclusion, this is the first clinical study on perianal tumors demonstrating that electrochemotherapy with cisplatin or bleomycin is an effective and safe local treatment of tumors in the perianal region in dogs. The advantages of this therapy are its simplicity, short duration of treatment sessions, low chemotherapeutic doses and insignificant side-effects, as well as the fact that the subject does not have to stay in the clinic. This first clinical use of electrochemotherapy of perianal tumors in dogs proved to be highly effective and will hopefully lead to a wider use of this therapy in veterinary medicine.

Acknowledgements

This work was supported by the Ministry of Education, Science and Sport of the Republic of Slovenia.

References

- Withrow SJ: Perianal tumours. *In*: Small Animal Clinical Oncology (Withrow SJ and MacEwen EG, eds). Philadelphia, PA: WB Saunders Co. 1996, pp. 261-267.
- Thomas RC and Fox LE: Tumors of the skin and subcutis, perianal (hepatoid) gland tumors. *In*: Cancer in Dogs and Cats (Morrison WB, ed). Baltimore, Williams & Wilkins 1998, pp. 497-498.
- Mir LM, Orlowski S, Belehradec JJr, Tessie J, Rols MP, Sersa G, Miklavcic D, Gilbert R and Heller R: Biomedical applications of electric pulses with special emphasis on antitumour electrochemotherapy. *Bioelectrochem Bioenerg* 38: 203-207, 1995.
- Cemazar M, Miklavcic D, Scancar J, Dolzan V, Golouh R and Sersa G: Increased platinum accumulation in SA-1 tumor cells after *in vivo* electrochemotherapy with cisplatin. *Br J Cancer* 79: 1386-1391, 1999.
- Sersa G, Cemazar M and Miklavcic D: Antitumour effectiveness of electrochemotherapy with cisdiamminedichloroplatinum (II) in mice. *Cancer Res* 55: 3450-3455, 1995.
- Mir LM, Glass LF, Sersa G, Teissie J, Domenge C, Miklavcic D, Jaroszeski MJ, Orlowski S, Reintgen DS, Rudolf Z, Belehradec M, Gilbert R, Rols MP, Belehradec J Jr, Bachaud JM, DeConti R, Stabuc B, Cemazar M, Coninx P and Heller R: Effective treatment of cutaneous and subcutaneous malignant tumors by electrochemotherapy. *Br J Cancer* 77: 2336-2342, 1998.
- Sersa G, Stabuc B, Cemazar M, Jancar B, Miklavcic D and Rudolf Z: Electrochemotherapy with cisplatin: potentiation of local cisplatin antitumor effectiveness by application of electric pulses in cancer patients. *Eur J Cancer* 34: 1213-1218, 1998.
- Sersa G, Stabuc B, Cemazar M, Miklavcic D and Rudolf Z: Electrochemotherapy with cisplatin: clinical experience in malignant melanoma patients. *Clin Cancer Res* 6: 863-867, 2000.
- Tozon N, Sersa G and Cemazar M: Electrochemotherapy: Potentiation of local antitumour effectiveness of cisplatin in dogs and cats. *Anticancer Res* 21: 2483-2486, 2001.
- Mir LM, Devauchelle P, Quintin-Colonna F, Delisle F, Doliger S, Fradelizi D, Belehradec J and Orlowski S: First clinical trial of cat soft-tissue sarcomas treatment by electrochemotherapy. *Br J Cancer* 76: 1617-1622, 1997.
- Rols MP, Tamzali Y and Teissie J: Electrochemotherapy of horses. A preliminary clinical report. *Bioelectrochemistry* 55: 101-105, 2002.
- Spugnini EP and Porrello A: Potentiation of chemotherapy in companion animals with spontaneous large neoplasms by application of electric pulses. *J Exp Clin Cancer Res* 22: 571-80, 2003.
- WHO Handbook for Reporting Results of Cancer Treatment. Geneva, Switzerland, WHO Offset Publications 48: 22-27, 1979.
- Morrison WB: Principles of treating chemotherapy complication. *In*: Cancer in Dogs and Cats (Morrison WB, ed). Baltimore, Williams & Wilkins 1998, pp. 387-397.
- Plumb DC: *Veterinary Drug Handbook*. 2nd ed. White Bear Lake, Pharma Vet Publishing 1995, pp. 86-87.
- Begg AC, Bartelink H, Stewart FA, Brown DM and Luck EE: Improvement of differential toxicity between tumor and normal tissues using intratumoral injection with or without a slow-drug-release matrix system. *NCI Monogr* 6: 133-136, 1988.
- Cemazar M, Milacic R, Miklavcic D, Dolzan V and Sersa G: Intratumoral cisplatin administration in electrochemotherapy: antitumor effectiveness, sequence dependence and platinum content. *Anticancer Drugs* 9: 525-530, 1998.
- Deurloo MJ, Kop W, van Tellingen O, Bartelink H and Begg AC: Intratumoral administration of cisplatin in slow-release devices. II. Pharmacokinetics and intratumoral distribution. *Cancer Chemother Pharmacol* 27: 347-353, 1991.
- Jekunen AP, Shalinsky DR, Hom DK, Albright KD, Heath D and Howell SB: Modulation of cisplatin cytotoxicity by permeabilization of the plasma membrane by digitonin *in vitro*. *Biochem Pharmacol* 45: 2079-2085, 1993.
- Kuang L, Yang DJ, Inoue T, Liu WC, Wallace S and Wright KC: Percutaneous intratumoral injection of cisplatin microspheres in tumor-bearing rats to diminish acute nephrotoxicity. *Anti-Cancer Drugs* 7: 220-227, 1996.
- Landrito JE, Yoshiga K, Sakurai K and Takada K: Effects of intralesional injection of cisplatin on squamous cell carcinoma and normal tissue of mice. *Anticancer Res* 14: 113-118, 1994.
- Smith JP, Stock E, Orenberg EK, Yu NY, Kanekal S and Brown DM: Intratumoral chemotherapy with a sustained-release drug delivery system inhibits growth of a human pancreatic cancer xenografts. *Anti-Cancer Drugs* 6: 717-726, 1995.
- Steenenberg PA, Storm G, de Groot G, Claessen A, Bergers JJ, Franken MA, van Hoesel QG, Wubs KL and de Jong WH: Liposomes as a drug carrier system for cis-diamminedichloroplatinum (II). II. Antitumor activity *in vivo*, induction of drug resistance, nephrotoxicity and Pt distribution. *Cancer Chemother Pharmacol* 21: 299-307, 1988.
- Vadiee K, Siddik ZH, Khokhar AR, al-Baker S, Sampedro F and Perez-Soler R: Pharmacokinetics of liposome-entrapped cis-bis-neodecanoato-trans-R,R-1,2-diamminocyclohexaneplatinum (II) and cisplatin given *i.v.* and *i.p.* in the rat. *Cancer Chemother Pharmacol* 30: 365-369, 1992.
- Sersa G, Cemazar M and Rudolf Z: Electrochemotherapy: advantages and drawbacks in treatment of cancer patients. *Cancer Ther* 1: 133-142, 2003.
- LaRue SM, Gillette SM and Poulson JM: Radiation therapy of thoracic and abdominal tumors. *Semin Vet Med Surg* 10: 190-196, 1995.

Received August 6, 2004

Revised December 12, 2004

Accepted February 3, 2005